

SemNaturalProduct2017

by Rina Priastini Susilowati

Submission date: 21-Jun-2019 11:42AM (UTC+0700)

Submission ID: 1145750946

File name: Turnitin_Proceeding_SeminarNaturalProduct_2017.pdf (893.62K)

Word count: 3002

Character count: 15131

SUBCHRONIC TOXICITY TEST OF MAJA (*Aegle marmelos* L.) CORR FRUIT EXTRACT ON MICE (*Mus musculus*) LIVER AND KIDNEY

Rina Priastini Susilowati

Department of Biology, Faculty of Medicine Krida Wacana Christian University Jakarta
E-mail: rinapriastini67@gmail.com

ABSTRACT

Maja plants (*Aegle marmelos* L.) Corr is a plant that is widely used as a medicinal plant. Toxicity test is a test to observe a pharmacological activity of a compound and detecting the toxic effect of a substance on a biological system (the body). Toxicity test was conducted to determine the security level of consumption use of a compound, one of which is a toxicity test on the plant in the form of traditional medicine. One type of toxicity tests that aimed to determine the short-term toxic effects are subchronic toxicity test. This study aimed to analyze the histopathological changes in the liver and kidneys of mice after administration maja fruit extracts are subchronic between the treatment group and the control group.

Experimental research design with Post Test Only Controlled Group Design. A sample of 25 Balb C mice were divided into one control group and 4 treatment groups. Maja fruit extract conducted orally through a sonde for 3 months. The treatment group was divided into a control group (K) were given distilled water, the treatment group of maja fruit extract a dose of 50 mg/kg body weight (P1), a dose of 100 mg/kg body weight (P2), a dose of 150 mg/kg body weight (P3) and a dose of 200 mg/kg body weight (P4). After three months of terminations done, is taken to the liver and kidneys then made preparations of their histology. Observations carried out on inspection toxic symptoms of liver and kidney weight ratio to body weight and histopathological changes in the liver and kidneys of mice. The data obtained were analyzed using one-way Anova, if there is a significant difference, and then tested further by Duncan 5% and 1%. It also conducted a linear regression and correlation.

From the findings, it seemed that the maja fruit extract with duration of 3 months showed no significant influence on the weight of the liver, kidneys and body weight of mice up to a dose of 200 mg/kg body weight. However, maja fruit extract experienced a significant difference in the histopathological changes in the liver and kidneys of mice, particularly at doses of 200 mg/kg body weight.

The results of calculations score histopathological changes in the liver and kidneys of mice in the experimental group showed that the higher the dose given, the higher the degree of damage to the tissue of liver and kidneys, especially at a dose of 200 mg/kg body weight.

Keywords: maja, subchronic toxicity test, liver and kidney histopathology

INTRODUCTION

There is an increasing number of people with diabetes each year as well as the cost of treatment of diabetes mellitus are expensive, especially if accompanied by clinical complications encourage people to try traditional medicine that can be used as an alternative treatment. One of these plants is a maja plant (*Aegle marmelos*). The use of complementary traditional medicine which include herbal medicines in the treatment of various diseases has expanded rapidly in both developed and developing countries, attributable to affordability, accessibility and efficacy.¹ Maja fruit contains tannin components 9%, while in the skin of the fruit reaches 20%.² The chemical components of tannins in the skin maja fruit can be used as a drug. Tannins are secondary metabolites of the active compound class of phenol compounds are known to have some efficacy as an astringent, anti-diarrhea, anti-bacterial and antioxidant.³ Astringents can precipitate proteins on the surface of the mucous membrane of the small intestine and form a layer that protects the intestine, thus inhibiting the absorption of glucose and increase the rate of blood glucose is not too high, therefore reducing blood glucose levels.⁴ In addition to inhibiting the absorption of glucose, tannins can also reduce digestibility by binding to proteins in the intestine.^{5,6}

Some groups of compounds that can cause toxic effects found in plants which partially soluble in fat and can be bio-accumulative. When the plants are consumed without the recommended dose, the compounds are then stored will be toxic and accumulate in tissues and organs of the body, one of them in the liver and kidneys. The liver and kidneys can be affected by adverse effects due to toxic compounds responsible for metabolizing a wide variety of compounds. In the liver and kidneys, the compounds will undergo bio-transformation. In addition, the process also plays a role in ending the compound work in the body.

Some of the active compound is known to have toxic effects to the body by way of toxicity testing. Toxicity testing aims to determine the effect of short term, long term and an appropriate dose of a substance containing the active compound.⁶ Therefore, based on the above background, it is necessary to toxicity testing. This may be because there are some of the content of the allegedly maja fruit extracts may be harmful to human health if consumed in the long term and that has not been recommended dose. This research was conducted toxicity tests with sub-chronic toxicity testing in the form of fruit extracts maja against severe liver and kidney, liver and kidney histopathologic changes in male mice.

MATERIALS AND METHODS

Plant preparations and extraction

For the purposes of maja fruit extracts can be made by following these steps:maja fruit cut into small pieces, then chopped or crushed into powder (supplied seeds and rind), added water at a ratio of 1: 1, meaning 1 maja chopped fruit coupled with 1 liter of water and stir until completely blended, left or fermented in a sealed bucket for approximately 12 hours. In the filter before use. Results of maja fruit extracts can be used directly.

Sample

In this study, the cage mice used as many as five pieces, each cage is filled by 5 mice, totally used 25 mice, age 2 month and average body weight 20-30 g, enclosure 1 as a control and was not given maja fruit extracts (*Aegle marmelos*) orally (by using a sonde), and four next be accorded treatment maja fruit extracts (*Aegle marmelos*) each 50 mg/kg b.wt, 100 mg/kg b.wt, 150 mg/kg b.wt and 200 mg/kg b.wt. Maja fruit extract conducted for 3 months.

Subchronic Toxicity Test

Organs of sacrificed animals, namely liver and kidneys were excised, washed with normal buffered saline, weighed to obtain absolute organ weight (AOW) and observed macroscopic. The relative organ weights (ROW) were calculated for each rat using the formula :relative organ weight equal with absolute organ weight divide it body weight at sacrificed times to 100%.

Statistics

Data were analyzed using SPSS 23 for Windows. The experimental results were expressed as the Mean \pm standard error mean (SEM). Data were assessed by one-way Anova for body weight, liver weight and kidney weight, followed by Kruskal Wallis test for histopathologic changes of liver and kidney. Values for which $p < 0,05$ was considered as statistically significant.

RESULTS AND DISCUSSION

Weight graph observations strains of mice Balb C after administration maja fruit extract (*Aegle marmelos*), during 3 months is shown in Figure 1.

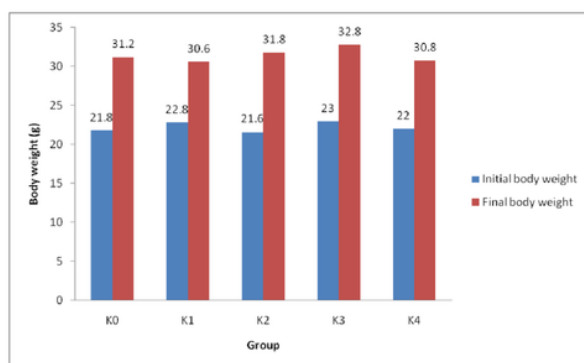


Figure 1. Graph of mice body weight changes in the control and treatment group

In subchronic studies, all mice used for the study appeared normal before, during and post-treatment. Mortality was not recorded at all dose levels used for the study: 50, 100, 150 and 200 mg/kg b.wt. The results of the effect of the extract on the body weight of the animals compared with vehicle is as shown in Figure 1. There were no significant increases in the weight of animals treated group with maja fruit extract until dose 200 mg/kg b.wt ($p > 0,05$).

The body weight changes serve as a sensitive indication of the general health status of animals. Figure 1 shows that the increase in body weight of mice every day in all groups, but the increase in body weight of mice in the treatment group maja fruit extract dose of 200 mg/kg body weight tend to be lower when compared to other groups. Weight loss can give you an idea animal health and is one of the parameters to determine the toxic effects of a compound.⁷ The crude extract may have been metabolized to a toxic end product which could interfere with gastric function and decreased food conversion efficiency.⁸

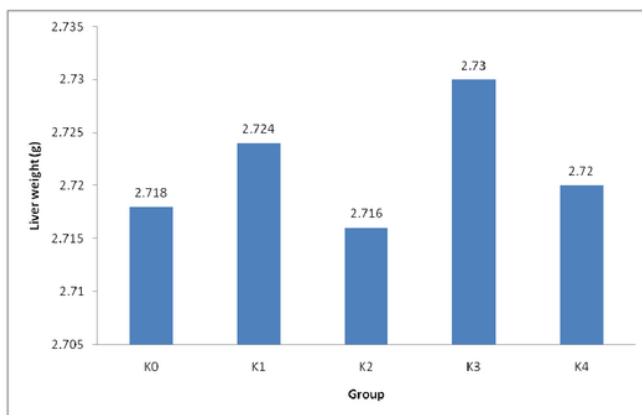


Figure 2. Graph of mice liver weight changes in the control and treatment group

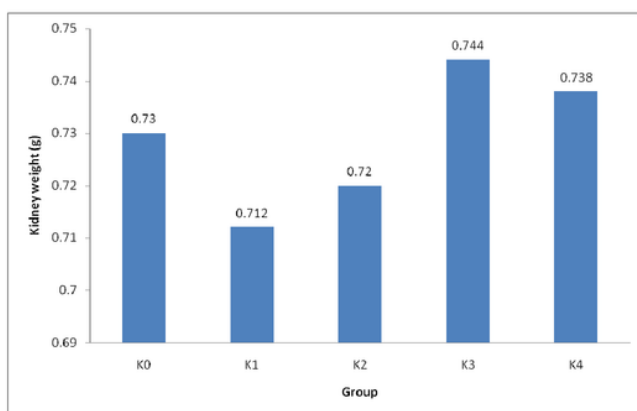


Figure 3. Graph of mice kidney weight changes in the control and treatment group

Macroscopic examination did not show any changes in the color of organs of the treated animals compared with control. There were no significant changes in the relative weights of the liver and kidney of mice. All other determinations showed no significant difference from control group.

Histology liver sinusoidal control group, the treatment group of maja fruit extract (*Aegle marmelos*) dose of 50 mg/kg b.wt and 100 mg/kg b.wt and showed normal sinusoidal (no dilation or widening). While the treatment group of maja fruit extract dose of 150 mg/kg b.wt and 200 mg/kg b.wt showed the dilatation of the sinusoidal.

Liver sinusoidal is blood vessels tortuous, coated with epithelial cell-rise is not intact, separated by a space underneath of hepatocytes perisinusoidal. Sinusoidal receives blood from the portal vein and the hepatic artery, then feeds into the central vein. There is a wall consisting of a sinusoidal epithelial cells form the lining is not intact. Hepatocytes and sinusoidal limited by epithelial gap containing microvilli of hepatocytes. It facilitates the direct contact between the surface of hepatocytes and sinusoidal so as to facilitate the exchange of macromolecules including toxicant.¹⁰

Based on the results of microscopic observation of the liver can be seen that the structure of hepatocytes are hydropic degeneration, fatty degeneration and necrosis of hepatocytes is very different from normal. In the normal liver tissue visible cell nuclei were still visible, the cytoplasm is not damaged, and the arrangement of the radial hepatocyte cells from the central to the peripheral vein.¹¹ While on the liver tissue looks abnormal cell nuclei undergo degeneration that hydropic degeneration and fatty degeneration and cell nuclei will undergo necrosis.

Based on the Kruskal Wallis test results obtained $\text{sig.} > 0.05$ which means there is no significant difference between the control group and the treatment group maja fruit extracts up to a dose of 200 mg/kg b.wt against liver cell damage in the form of fatty degeneration, hydropic degeneration and necrosis of liver cells.

Based on the Kruskal Wallis test results obtained $\text{sig.} > 0.05$, which means there is no significant difference between the control group and the treatment group of maja fruit extracts up to a dose of 200 mg/kg b.wt of the proximal tubular damage and another damage in the form of renal cell necrosis.

Kidney is the organ after the liver, most often the target of destruction by chemical substances. This is due to many chemicals that are excreted through urine.¹² Kidneys are the organs that have an important role in the body to dispose of metabolic waste and toxins in the form of urine. In addition, the kidneys also play a role in maintaining the balance of water, salts and electrolytes. No less important is the kidney is an organ that is susceptible to the influence of chemical substances, since this organ receives 25-30% circulation of blood to be cleaned, so as filtration organ pathological alterations likelihoods is very high.¹³

The results showed that different doses of majafruit extract (*Aegle marmelos*) given to mice caused no significant change in the structure of the kidney histology. Although the treatment group of maja fruit extract at a dose of 150 mg/kg b.wt and 200 mg/kg b.wt cause proximal tubular damage and renal cell necrosis. Kidneys are vital organs. This is because the function to excrete the remnants of metabolism. Kidney damage due to toxic substances can be identified based on histopathologic changes, namely acute tubular necrosis were morphologically characterized by proximal tubular epithelial extrusion. Proximal tubular epithelial cells sensitive to anoxia and easily destroyed due to poisoning by contact with materials that are excreted through the kidneys. Proximal tubular epithelial cells sensitive to anoxia and easily destroyed due to poisoning by contact with materials that are excreted through the kidneys. Changes in kidney histological structure is certainly influenced by the amount of the compound into the body. Other factors that may cause damage to the kidneys is the kidney's ability to concentrate xenobiotic substance inside the cell. If a chemical agent is actively excreted from the blood into the urine, chemicals beforehand accumulated in the proximal tubule, or if the chemical substance is reabsorbed from the urine then it will be through the tubular epithelial cells with high concentrations. As a result of the concentration process, these toxic substances will accumulate in the kidneys and cause damage to the kidneys.¹⁴

No change indicating damage of proximal tubule and cell necrosis, showed that the majafruit extract (*Aegle marmelos*) orally did not cause toxicity to the kidney tissue of mice. From the results obtained are very supportive in the use of majafruit extracts (*Aegle marmelos*) for humans because of the results of this study proved to be safe to use up to a dose of 200 mg/kg b.wt.

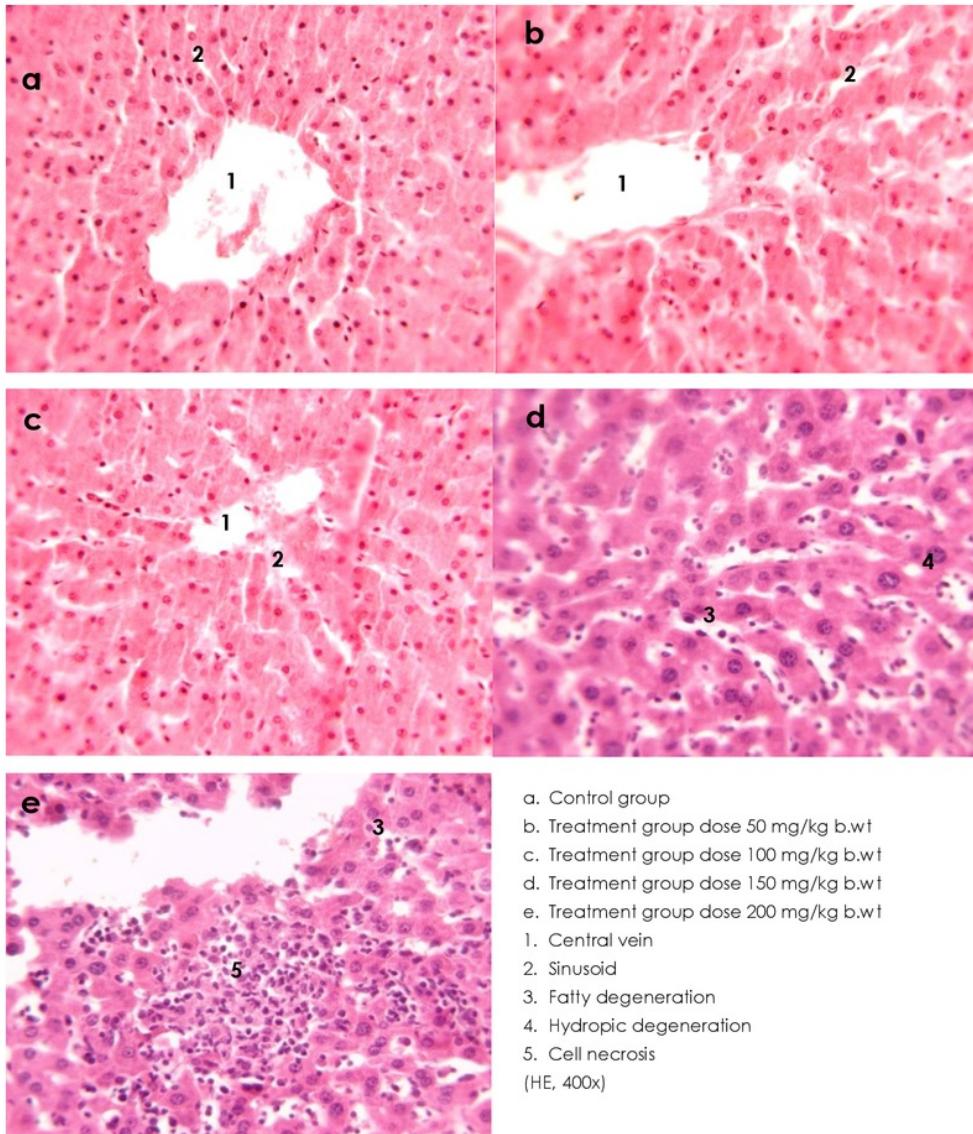
CONCLUSION

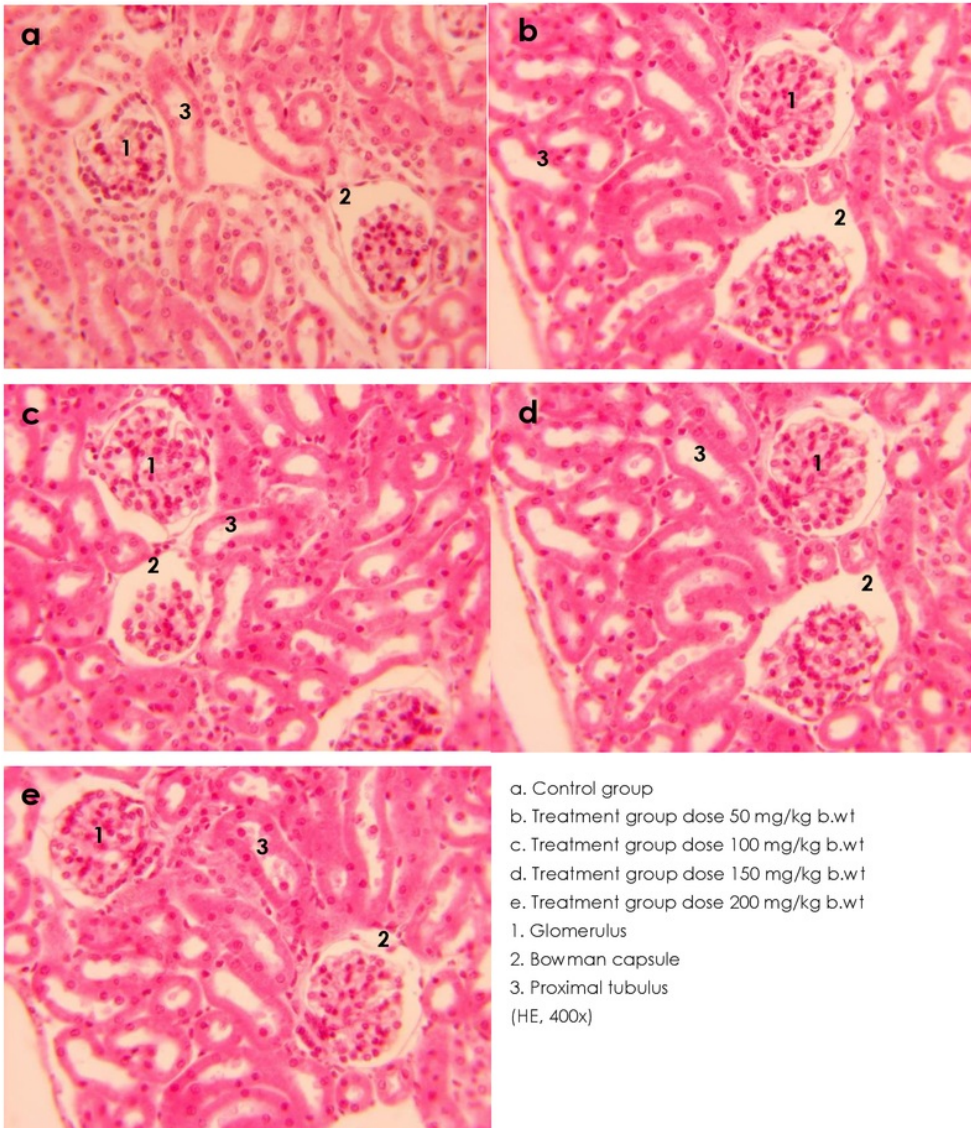
Maja fruit extract (*Aegle Marmelos*) to a dose of 200 mg/kg b.wt orally for 3 months did not cause changes in body weight, liver weight and kidney weight of mice, not cause histopathological changes in the liver of mice, although at a dose of 150 mg/kg b.wt and 200 mg/kg b.wt of fatty degeneration, hydropic degeneration and necrosis of liver cells, not cause histopathological changes in the kidneys of mice, although at a dose of 150 mg/kg b.wt and 200 mg/kg b.wt of proximal tubule damage and necrosis cells of the kidney.

REFERENCES

1. Salawu OA, Chindo BA, Tijani AY, Obidike IC, Salawu TA, Akingbasote AJ. African Journal of Pharmacy and Pharmacology. 2009; 3 (12): 621 – 626.
2. Chavda N, Mujapara A, Mehta SK, Dodia PP. Primary identification of certain phytochemical constituents of *Aegle marmelos* (L.) Corr. Serr responsible for antimicrobial activity against selected vegetable and clinical phatogen. International Journal of Physycal and Social Sciences. 2012; 2(6) : 194.
3. Hagerman AE. Tannin handbook. Miami : Departement of Chemistry and Biochemistry, Miami University; 2002.
4. Anggraeni AD. Pengaruh pemberian infusa biji alpukat (*Persea Americana* Mill.) terhadap kadar glukosa darah tikus Wistar yang diberi beban glukosa. Skripsi. Semarang : Universitas Diponegoro; 2006.
5. Widodo W. Tanaman beracun dalam kehidupan ternak. Malang : Universitas Muhammadiyah Malang Press; 2005.
6. Wirasuta, Gelgel MA, Niruri, 2. Toksikologi Umum (Buku Ajar). Bali : Jurusan Farmasi Fakultas MIPA Universitas Udayana; 2007.
7. Siburian, J. dan R. Marlinza. Efek pemberian ekstrak akar pasak bumi (*Eurycoma Longifolia* Jack) pada tahap prakopulasi terhadap fertilitas mencit (*Mus Musculus* L.) Betina. Biospecies. 2009; 2 (2): 24 - 30.
8. Chokshi D. Food and Chemical Toxicol.2007; 45: 32 – 40.
9. Daglia M, Rachi M, Papetti A, Lanni C, Govoni S, Gazzani G. In vitro and ex vivo antihydroxyl radical activity of green and roasted coffee. Journal Agric Food Chem. 2000; 48(5):1449-54.
10. Arifin H., dkk. Pengaruh pemberian akut ekstrak etanol daun capo (*Blumea balsamifera* L. DC) terhadap gambaran morfologis dan histologi hati mencit putih jantan. J Sains Teks Far. 2007; 12(2).

11. Hastuti SU. Pengaruh berbagai dosis citrinin terhadap kerusakan struktur hepatosit mencit (*Mus musculus*) pada tiga zona lobulus hepar. Jurnal Kedokteran Brawijaya. 2008; XXII(3).
12. Gerhastuti BC. Pengaruh pemberian kopi dosis bertingkat per oral selama 30 hari terhadap gambaran histologi ginjal tikus Wistar. Semarang : Universitas Diponegoro; 2009.
13. Corwin EJ. Buku saku patofisiologi. Alih Bahasa Brahm U Pedit. Jakarta : Penerbit Buku Kedokteran EGC; 2001.
14. Yuanita DA. Pengaruh pemberian teh kombucha dosis bertingkat per oral terhadap gambaran histologi ginjal mencit Balb/C. Semarang : Fakultas Kedokteran Universitas Diponegoro; 2008.





SemNaturalProduct2017

ORIGINALITY REPORT

22%

SIMILARITY INDEX

20%

INTERNET SOURCES

11%

PUBLICATIONS

21%

STUDENT PAPERS

MATCH ALL SOURCES (ONLY SELECTED SOURCE PRINTED)

12%

★ Submitted to Kwame Nkrumah University of
Science and Technology

Student Paper

Exclude quotes On

Exclude bibliography On

Exclude matches < 15 words

SemNaturalProduct2017

GRADEMARK REPORT














FINAL GRADE

/30

GENERAL COMMENTS

Instructor

PAGE 1

-  **Article Error** You may need to use an article before this word.
-  **Article Error** You may need to use an article before this word.
-  **Article Error** You may need to use an article before this word.
-  **Article Error** You may need to use an article before this word.
-  **Sp.** This word is misspelled. Use a dictionary or spellchecker when you proofread your work.
-  **Missing ","** You may need to place a comma after this word.
-  **S/V** This subject and verb may not agree. Proofread the sentence to make sure the subject agr with the verb.
-  **Prep.** You may be using the wrong preposition.
-  **Prep.** You may be using the wrong preposition.
-  **P/V** You have used the passive voice in this sentence. Depending upon what you wish to emphasize in the sentence, you may want to revise it using the active voice.
-  **Verb** This verb may be incorrect. Proofread the sentence to make sure you have used the corr form of the verb.
-  **Wrong Article** You may have used the wrong article or pronoun. Proofread the sentence to make sure that the article or pronoun agrees with the word it describes.
-  **Wrong Article** You may have used the wrong article or pronoun. Proofread the sentence to make sure that the article or pronoun agrees with the word it describes.



Sp. This word is misspelled. Use a dictionary or spellchecker when you proofread your work.

PAGE 2



S/V This subject and verb may not agree. Proofread the sentence to make sure the subject agrees with the verb.



Possessive This word may be a plural noun and may not need an apostrophe.



Possessive This word may be a plural noun and may not need an apostrophe.



Possessive This word may be a plural noun and may not need an apostrophe.



P/V You have used the passive voice in this sentence. Depending upon what you wish to emphasize in the sentence, you may want to revise it using the active voice.



Run-on This sentence may be a run-on sentence. Proofread it to see if it contains too many independent clauses or contains independent clauses that have been combined without conjunctions or punctuation. Look at the "Writer's Handbook" for advice about correcting run-on sentences.



Article Error You may need to remove this article.



Article Error You may need to remove this article.



Sp. This word is misspelled. Use a dictionary or spellchecker when you proofread your work.



Prep. You may be using the wrong preposition.



P/V You have used the passive voice in this sentence. Depending upon what you wish to emphasize in the sentence, you may want to revise it using the active voice.



Article Error You may need to use an article before this word. Consider using the article **the**

PAGE 3



Frag. This sentence may be a fragment or may have incorrect punctuation. Proofread the sentence to be sure that it has correct punctuation and that it has an independent clause with a complete subject and predicate.



Article Error You may need to use an article before this word. Consider using the article **the**



Sp. This word is misspelled. Use a dictionary or spellchecker when you proofread your work.



S/V This subject and verb may not agree. Proofread the sentence to make sure the subject agrees with the verb.



Proofread This part of the sentence contains a grammatical error or misspelled word that makes your meaning unclear.



S/V This subject and verb may not agree. Proofread the sentence to make sure the subject agrees with the verb.



S/V This subject and verb may not agree. Proofread the sentence to make sure the subject agrees with the verb.



P/V You have used the passive voice in this sentence. Depending upon what you wish to emphasize in the sentence, you may want to revise it using the active voice.



Proofread This part of the sentence contains a grammatical error or misspelled word that makes your meaning unclear.



Missing ", " You may need to place a comma after this word.

PAGE 4



Proofread This part of the sentence contains a grammatical error or misspelled word that makes your meaning unclear.



Article Error You may need to remove this article.



Article Error You may need to use an article before this word. Consider using the article **the**.



Article Error You may need to use an article before this word.



Missing ", " You may need to place a comma after this word.





Proofread This part of the sentence contains a grammatical error or misspelled word that makes your meaning unclear.


PAGE 5





Proofread This part of the sentence contains a grammatical error or misspelled word that makes your meaning unclear.


 **Sp.** This word is misspelled. Use a dictionary or spellchecker when you proofread your work.


 **Article Error** You may need to remove this article.

 **Wrong Form** You may have used the wrong form of this word.


 **Article Error** You may need to use an article before this word.


 **Sp.** This word is misspelled. Use a dictionary or spellchecker when you proofread your work.


 **Wrong Article** You may have used the wrong article or pronoun. Proofread the sentence to make sure that the article or pronoun agrees with the word it describes.

 **Missing ","** You may need to place a comma after this word.


PAGE 6


 **Sp.** This word is misspelled. Use a dictionary or spellchecker when you proofread your work.


 **Sp.** This word is misspelled. Use a dictionary or spellchecker when you proofread your work.


 **Article Error** You may need to use an article before this word.


 **Missing ","** You may need to place a comma after this word.


 **Proofread** This part of the sentence contains a grammatical error or misspelled word that makes your meaning unclear.

 **Sp.** This word is misspelled. Use a dictionary or spellchecker when you proofread your work.

 **S/V** This subject and verb may not agree. Proofread the sentence to make sure the subject agrees with the verb.

 **P/V** You have used the passive voice in this sentence. Depending upon what you wish to emphasize in the sentence, you may want to revise it using the active voice.

 **P/V** You have used the passive voice in this sentence. Depending upon what you wish to emphasize in the sentence, you may want to revise it using the active voice.

 **Article Error** You may need to use an article before this word.



Article Error You may need to remove this article.

PAGE 7



Sp. This word is misspelled. Use a dictionary or spellchecker when you proofread your work.



Sp. This word is misspelled. Use a dictionary or spellchecker when you proofread your work.



Wrong Article You may have used the wrong article or pronoun. Proofread the sentence to make sure that the article or pronoun agrees with the word it describes.

PAGE 8

PAGE 9

PAGE 10
